

A retrospective study investigating how common serrated adenocarcinomas are using morphological and immunohistochemical data

Authors

Andrade, Ana C.
Arnaout, Abed

Introduction

Colorectal cancer (CRC) is the third most common cancer worldwide and affects the large bowel which is primarily composed of the colon and rectum.

CRC has traditionally been thought to develop via the established adenoma-carcinoma sequence. This omitted hyperplastic or serrated polyps from being thought to develop into CRC. However, in the last decade it has become clear that this view was incorrect and that the proposed serrated pathway may account for up to one third of CRCs. BRAF mutation incites the development of serrated lesions in the form of microvesicular hyperplastic polyps (HPs) or sessile serrated polyps (SSPs). These lesions, prone to methylation of CpG islands in the promoter regions of genes, undergo epigenetic silencing. MLH1 epigenetic silencing results in sporadic tumours with microsatellite instability (MSI). Tatsumi, et al., 2005 reported that most conventional adenomas and adenocarcinomas expressed a CK7-/CK20+ pattern compared to the CK7+/CK20+ pattern of expression displayed in the greater part of serrated adenoma, HPs and serrated adenocarcinomas. Therefore, this project compared CK7 and CK20 markers on resected adenocarcinomas to see which express both and to examine the tumours for possible serrated configuration in order to reaffirm the serrated pathway.

Methods

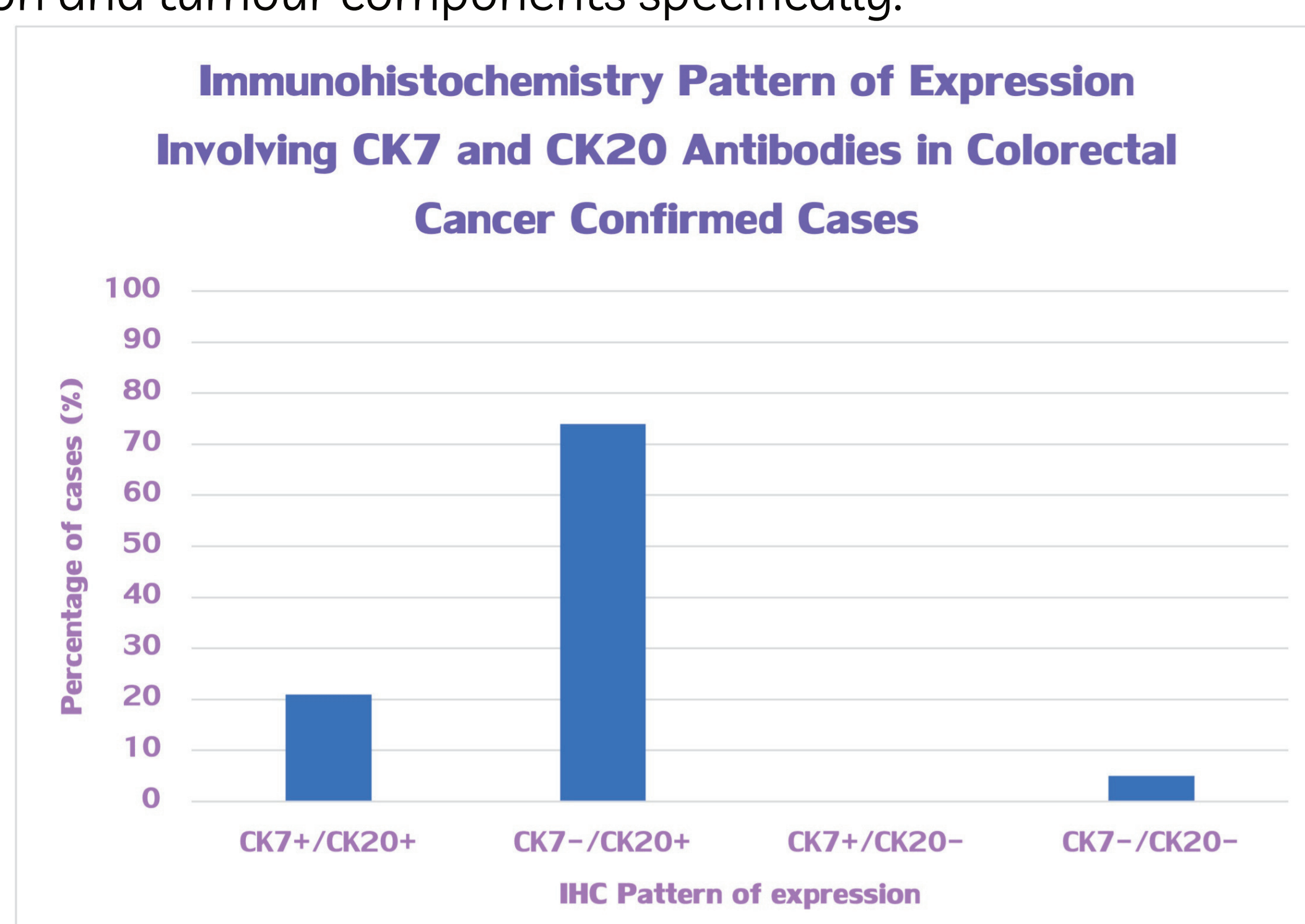
For this study, 100 cases of patients, previously submitted to a resection procedure and consequently diagnosed with a primary CRC, were randomly selected from St. George's Hospital Cellular Pathology department database, between the years of 2018 and 2021.

Immunohistochemistry (IHC) staining using CK7 (clone: SP52; pre-diluted; ROCHE Diagnostics, Switzerland) and CK20 (clone: SP33; pre-diluted; ROCHE Diagnostics, Switzerland) antibodies was carried out via Ventana automatic Immunostainer (BenchMark Ultra IHC/ ISH System). Immunohistochemistry was performed from formalin-fixed, paraffin-embedded blocks on the selected 100 cases of previously diagnosed primary CRC.

Results

Haematoxylin and eosin (H&E) analysis on 100 cases of primary CRC samples identified serrated morphology on 37% of cases.

CK7+/CK20+ pattern of expression was present in 21% of cases. 11% of CRC cases studied displayed general CK7+/CK20+ expression, as well as that same pattern in both serration and tumour components specifically.

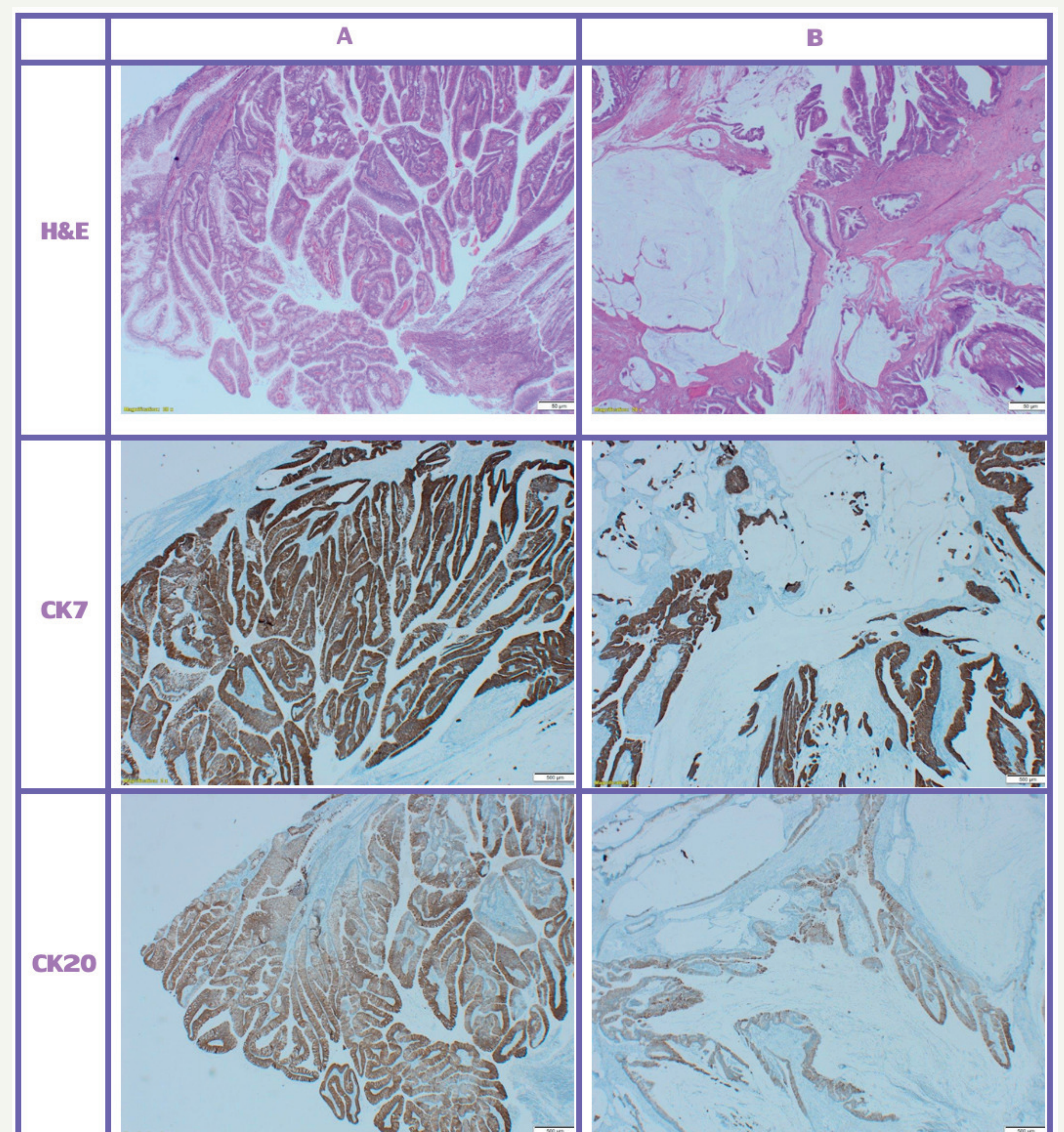


The figure above displays the IHC pattern of expression (%) involving both CK7 and CK20 antibodies in CRC confirmed cases (n=100).

Discussion and Conclusion

In this study 21% of the CRC cases displayed a CK7+/CK20+ expression pattern. This statistically significant evidence supports Kiremitci, et al., 2020 reports of CRC's arising from serrated lesions displaying CK7+ expression. Evidence gathered in this study allows for a link between CK7+/CK20+ patterns of expression in CRC case with the serrated neoplasia pathway. As 37% of all CRC cases presenting serrated morphology, via H&E examination, in combination with the evidence gathered that 21% of all CRC cases displayed CK7+/CK20+ pattern of expression strengthens the link between CRC and the serrated neoplasia pathway. 11% of all CRC cases studied displayed general CK7+/CK20+ expression, as well as that same pattern in both serration and tumour components specifically. This data consequently supports theories by Hirano, et al., 2019 who considered that the serrated carcinoma pathway is estimated to account for approximately 10–30% of all CRCs.

Establishing the fact that serrated adenocarcinomas can be distinguished from traditional CRCs, we proposed that CK7 and CK20 IHC analysis alongside adequate sampling of the tumour & adjacent non-neoplastic colorectal mucosa should be implemented when handling specimens. Increasing awareness in the scientific community in the reporting of serrated lesions, may consequently benefit patients with their likely prognosis and treatment.



Immunohistochemistry expression of CK7+ and CK20+ in a case of possible serrated adenocarcinoma (S+/T+).

Histological images (magnification 2x) showing: (A) H&E of the tumour component with corresponding CK7+ and CK20+ IHC staining. (B) H&E of the serrated component with corresponding CK7+ and CK20+ IHC staining.

Related literature

Crockett, S. D., Snover, C. D., Ahnen, D. J. & Baron, J. A., 2015. Sessile Serrated Adenomas: An Evidence-Based Guide to Management. *Clinical Gastroenterology and Hepatology* 2015;13:11-26, Volume 13, pp. 11-26.
Hirano, D., Urabe, Y., Tanaka, S. & Nakamura, K., 2019. Early-stage serrated adenocarcinomas are divided into several molecularly distinct subtypes. *PLOS ONE*.
Humpath, 2012. *Humpath*. [Online] Available at: <https://www.humpath.com/spip.php?article18500> Accessed December 2021.
Kiremitci, S., Ersoz, C. C., Soyas, B. & Ensari, A., 2020. Gastric and small intestinal traditional serrated adenomas: a detailed morphologic and immunohistochemical analysis. *Turk J Gastroenterol* 2020, pp. 441-450.
Tatsumi, N. et al., 2005. Expression of Cytokeratins 7 and 20 in Serrated Adenoma and Related Diseases. *Digestive Diseases and Science*, 50(9), pp. 1741- 1746.
Xi, Y. & Xu, P., 2021. Global colorectal cancer burden in 2020 and projections to 2040. *Elsevier*.

Funding Acknowledgement

This work was completed as part of an MSc in Biomedical Science (Online) with Biomed Online at University of Greenwich and supported by the Department of Cellular Pathology, St. George's Hospital/ London, England.