



The Royal College of **Pathologists**
Pathology: the science behind the cure

Diploma of Expert Practice in Histological Dissection

Examination 2020

Paper 1

Mandatory modules short-answer questions

120 minutes

1. Attempt **all** questions
2. Questions may be answered in any order
3. Each question is worth a total of 20 marks
4. You must transfer your answers directly into the answer booklet
5. Begin each new answer on a new page

The question paper is not to be removed from the examination room

Q1. Clinical Governance

- a. Describe the precautions would you take when performing specimen dissection on a high-risk specimen. (10 marks)
- b. Give examples of the events that should be included in an incident log for specimen dissection. (10 marks)

Q2. General Principles of Specimen Dissection

- a. You have been asked to write an SOP for the operation and maintenance of an underflow dissection bench. What are the main points you would include? (7 marks)
- b. Using the example of a skin ellipse illustrate with diagrams three common techniques used for sectioning at cut-up. (3 marks)
- c. Describe the advantages and disadvantages of each of the different methods and how a clinical history may influence block taking. (6 marks)
- d. Give definition and clinical relevance of the following medical terminology. (2 marks each)
 - i. Postmenopausal Bleeding (PMB)
 - ii. Sentinel Lymph Node Biopsy (SLNB)

Q3. Surgical Procedures

- a. Describe the four following surgical procedures which are available to a clinician investigating lung pathology and their clinical indications for use. (3 marks each)
 - i. EBUS
 - ii. VATS wedge resection
 - iii. Lobectomy
 - iv. Pneumonectomy
- b. Using specific examples compare and contrast the following surgical procedures. (4 marks each)
 - i. Breast- vacuum assisted biopsy versus core biopsy
 - ii. Endometrium-curettage versus pipelle

Q4. Pathological Processes

You receive an appendix specimen with clinical history “appendicitis”.

- What are the underlying pathological processes of acute appendicitis? (4 marks)
- Describe the possible macroscopic histopathological features present relative to this specimen. (6 marks)
- Cell death has two major mechanisms, name them and give a definition of both. (4 marks)
- Outline how these two processes differ. (6 marks)

Q5. Anatomical Nomenclature

- Identify the five abdominopelvic regions (A to E) on the diagram below and for each state a disease associated with that region. (10 marks)

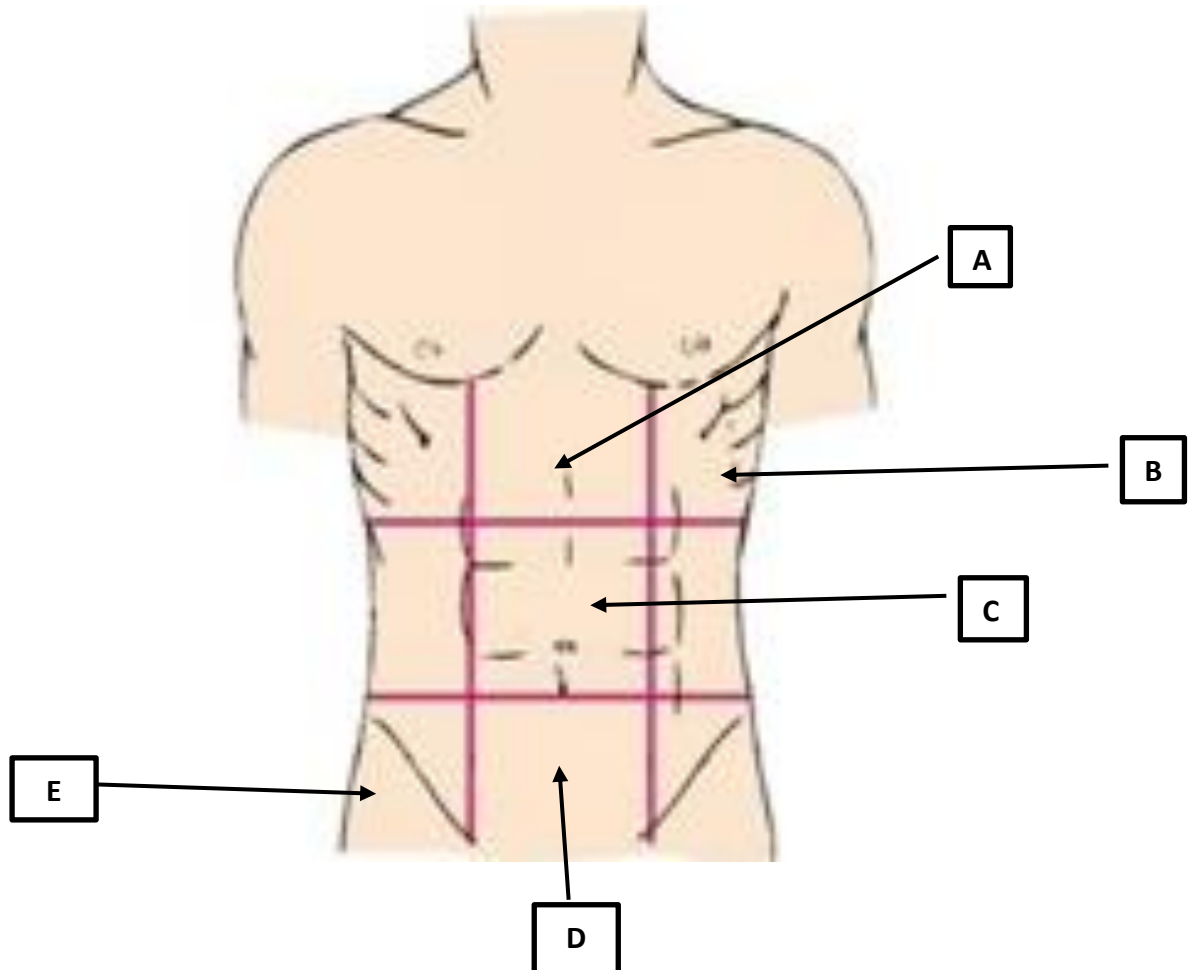


Figure 1 – Abdominopelvic Regions

- List five different types of epithelia. For each of the five draw its microscopic appearance and state a location where it is found in the body. (10 marks)



The Royal College of Pathologists
Pathology: the science behind the cure

Diploma of Expert Practice in Histological Dissection

Examination 2020

Paper 2

Optional modules short-answer questions

120 minutes

1. Attempt 6 from 11 questions
2. Each question is worth 20 marks
3. You must transfer your answers directly into the answer booklet
4. Begin each new answer on a new page
5. Questions can be answered in any order

This question paper is not to be removed from the examination room.

Q1. Endocrine

- a. Give an account of the features that should be described while dissecting a total thyroidectomy specimen that has been submitted to the laboratory with the history of 'multinodular goitre'. (8 marks)

You receive a parathyroid specimen with the clinical details 'histopathology please'.

- b. How many parathyroids are commonly present on thyroid and where are they located? (2 marks)
- c. What are the common disease processes that result in the removal of the parathyroid glands? (2 marks)
- d. How would you describe, handle and dissect this specimen? (6 marks)

You receive a specimen comprising a number of pieces of pancreatic tissue with the clinical history 'chronic pancreatitis'.

- e. What are thought to be the underlying causes of chronic pancreatitis? (2 marks)

Q2. Skin

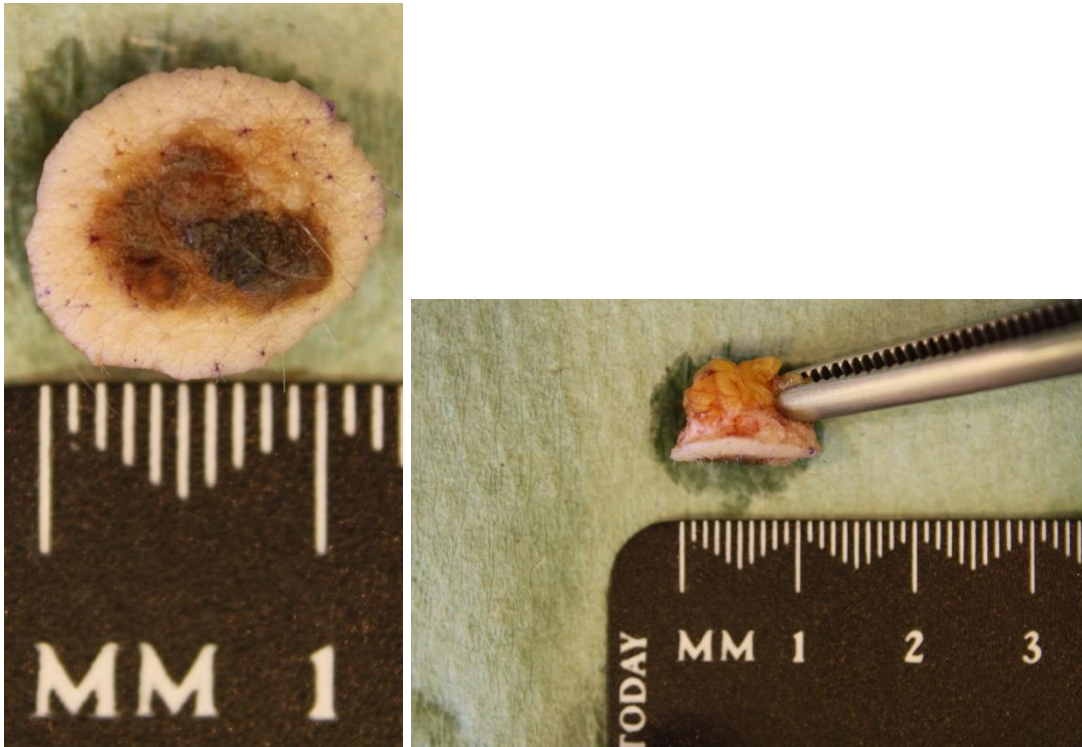
- a. Define the following surgical biopsy techniques and give an example of their application in the investigation of a cutaneous disease. (Two marks each)
- i. Punch biopsy
 - ii. Ellipse of skin
 - iii. Curettage
 - iv. Incisional biopsy

Two skin specimens arrive in the department on your day in dissection.

- b. Give a macroscopic description for **SPECIMEN A** seen below. (4 marks)

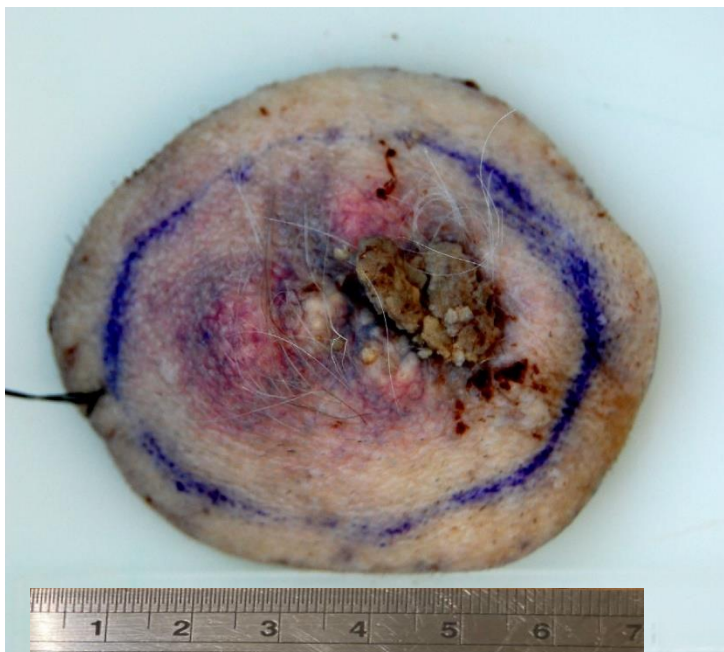
continued on next page

SPECIMEN A

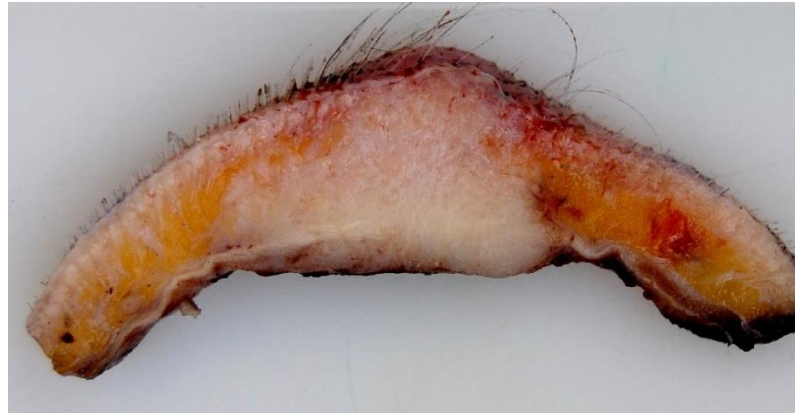


c. Give a macroscopic description for **SPECIMEN B** seen below. (4 marks)

SPECIMEN B (Scale in cm)

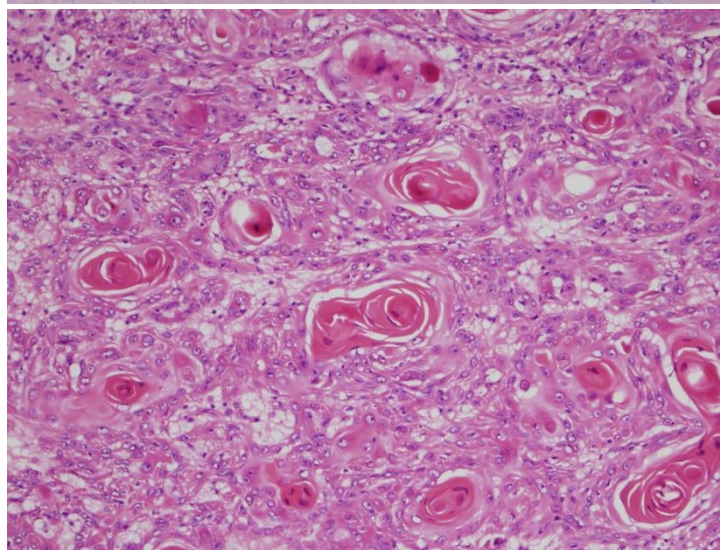
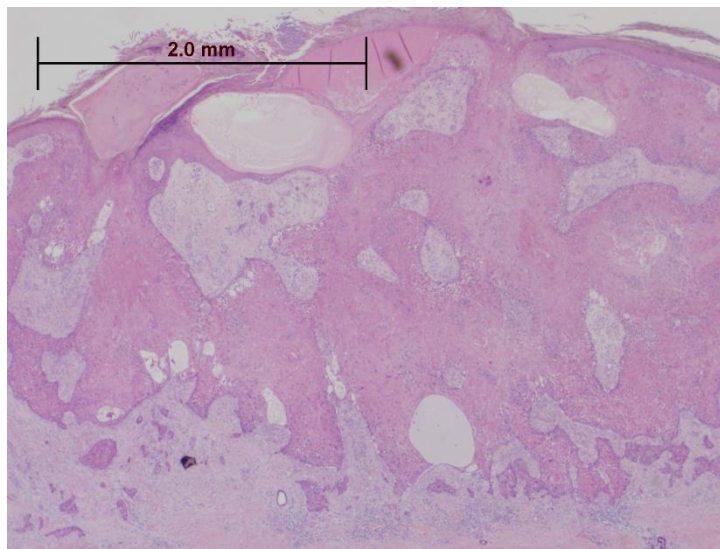


continued on next page



d. Give the **two** main differential diagnoses for the lesion seen in **SPECIMEN A**. (2 marks)

A microscopic image from the tumour from **SPECIMEN B** is shown below.



e. What is the diagnosis and what feature(s) in the histology allow you to reach that conclusion? (2 marks)

Q3. Breast

- a. Outline the cause and clinical presentation of the condition gynaecomastia. (3 marks)
- b. How would you describe, handle and dissect such a specimen? (4 marks)
- c. Describe two microscopic features of gynaecomastia. (2 marks)

An 18-year old female presented to her GP with a palpable breast lump which was mobile and well circumscribed.

- d. What is the differential diagnosis at this stage? (3 marks)

The patient was referred to the symptomatic breast clinic.

- e. Describe how the lesion would be assessed at the breast clinic. (3 marks)

Tests revealed a solid 26mm lesion diagnosed U2 B2.

- f. Explain the meanings of these diagnostic codes. (2 marks)
- g. Discuss the management options and any influencing factors on the treatment choices. (3 marks)

Q4. Osteoarticular and Soft Tissue

- a. For each of the following specimen types describe their aetiology, relevant macroscopic features and how you would normally dissect such specimens. (4 marks each)
 - i. Lipoma
 - ii. Ganglion cyst
- b. Identify four causes of synovitis giving an example of a pathological condition associated with each cause. (4 marks)

A synovial biopsy has been submitted to the laboratory for processing.

- c. Explain the clinical investigations of joint disease which may precede biopsy? (3 marks)
- d. How would this specimen be handled at dissection? (5 marks)

Q5. Cardiothoracic

a. What do the following abbreviations stand for? (1 mark each)

- i. VATS
- ii. CVA
- iii. SVCO
- iv. WG
- v. PE

b. Draw a diagram of the anterior aspect of the lungs showing anatomical features and relation to adjacent organs (6 marks)

You receive a pleural biopsy specimen with the clinical details "Dyspnoea. Pleural effusion. Pleural plaque"

c. Describe two possible methods of obtaining this sample giving any benefits or disadvantages. (4 marks)

An intact mitral valve has been submitted for examination.

d. Briefly discuss the possible reasons for resection and any related macroscopic features. (5 marks)

Q6. Gastrointestinal and Hepatobiliary

You receive an unopened gallbladder with the clinical details of cholelithiasis.

a. Outline the procedure you would follow to dissect and sample this specimen and the key elements of your macroscopic description. (8 marks)

b. What action would you take if you also identified an 13mm polypoid lesion projecting into the lumen in this same gallbladder specimen and briefly outline why would you take these actions. (6 marks)

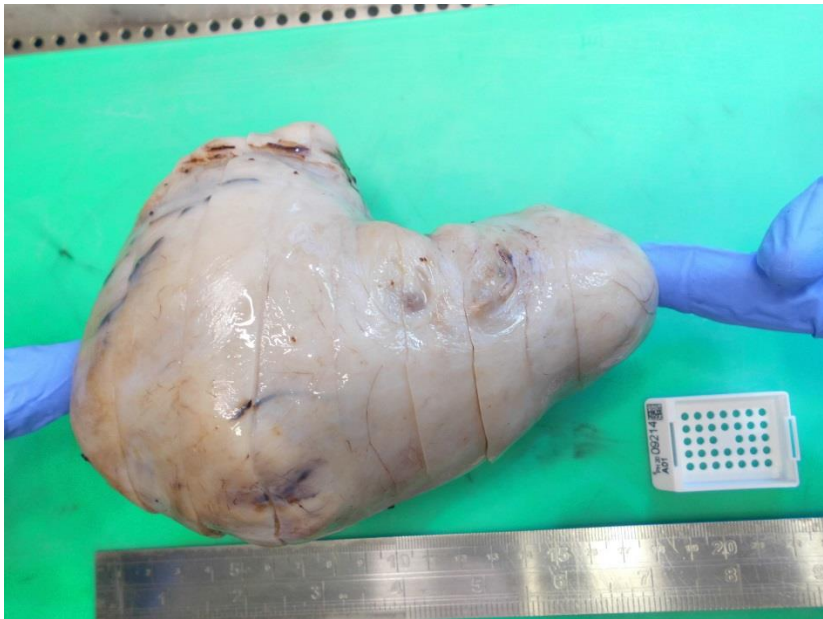
c. Describe the key macroscopic appearances which you would expect to see in rectal prolapsed specimen from a Delorme's procedure. (3 marks)

d. What blocks would you take to sample this specimen? (3 marks)

Q7. Gynaecological

- a. Describe the normal cut surface of a pre-menopausal ovary. (2 marks)
- b. Describe **four** benign cystic or solid ovarian lesions that you may encounter at the dissection bench and their typical appearance. Explain the rationale for sampling of these specimens. (3 marks each)

You receive the following specimen with the clinical details-myomectomy.



- c. Describe the cut surface and how you would sample this specimen. (3 marks)
- d. Describe the features of such a specimen that would cause concern at the dissection stage. (1 mark)
- e. What are possible clinical conditions for performing a myomectomy? (2 marks)

Q8. Genitourinary

You receive a specimen with the clinical details 'pyeloplasty for PUJ obstruction'

- a. What is 'PUJ obstruction' and how may it occur? (2 marks)
- b. How would you describe, handle and dissect this specimen? (5 marks)
- c. What may be the consequences of untreated PUJ obstruction? (2 marks)

Nephrectomy for adult polycystic kidney disease

- d. What is the cause of this condition? (1 mark)
- e. Briefly describe the macroscopic appearance of the specimen (3 marks)
- f. Explain, with reasons, the blocks you would take for this specimen. (3 marks)

Bladder biopsy

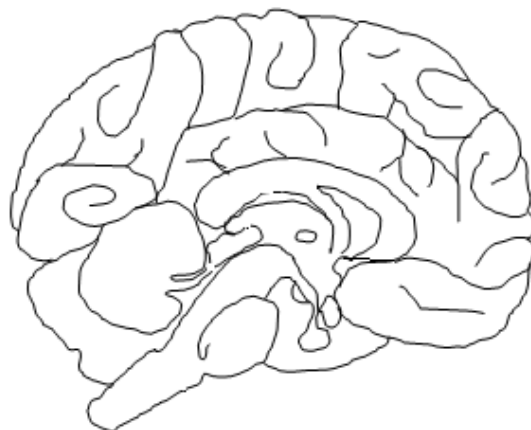
- g. Describe the microscopic appearances of a normal bladder biopsy. (4 marks)

Q9. Haemopoietic

- a. Describe the anatomy, the anatomical position and relations of the normal spleen. Illustrate your answer with the aid of a diagram. (4 marks)
- b. Discuss the main functions of the spleen. (4 marks)
- c. Describe the three most common reasons for submission of a spleen to the laboratory. (3 marks)
- d. What is thrombocytopenia and what are the major causes of it? (3 marks)
- e. What is the typical appearance of a spleen affected by thrombocytopenia? (2 marks)
- f. How would you handle a fixed spleen on the dissection bench where no specific reason for splenectomy is provided on the request form? (4 marks)

Q10. Neuromuscular

- a. Name two benign neoplasms that can derive from nerves and describe their macroscopic and microscopic main features (6 marks)
- b. Annotate the following structures on the given diagram and describe their function. (2 marks each)
 - i. Medulla
 - ii. Pineal body
 - iii. Corpus callosum
 - iv. Cerebellum



- c. Give a short account of the blocks that should be taken from a fresh muscle biopsy and a brief explanation of why. (6 marks)

Q11. Head and Neck

A 23 year old man presents with a painful swelling in his left upper neck which has been increasing in size. He has no other ENT symptoms and a flexible nasal endoscopy is unremarkable. Examination reveals a mobile, tender, soft swelling in the left level II neck.

- a. What are the possible differentials based on this information? (7 marks)

An ultrasound shows a cystic mass and an FNA is taken which shows brown mucoid pus like fluid containing anuclear keratinizing cells, squamous epithelial cells of varying maturity, frequent small to medium sized lymphocytes, cholesterol crystals and background amorphous debris. There is no squamous cytological atypia and no p16 expression.

- b. What is the most likely diagnosis based on this report and why? Briefly describe about the aetiology of this condition. (5 marks)

The mass was surgically removed and sent for histological examination.

- c. Describe the typical macroscopic appearance of this specimen and how this specimen would be handled at the dissection bench and the reasons for your block selection. What would you expect to see microscopically? (8 marks)